

**Mystery Boxes, X-Rays, and Radiology**  
**"a way of knowing science"**

**NAME:** \_\_\_\_\_

**Radiology**

**YOU BE THE RADIOLOGIST!**

Using X-ray data to make a medical diagnosis and to further experience using inferences in science as a way of knowing.

Write your name and school name on the lines below:

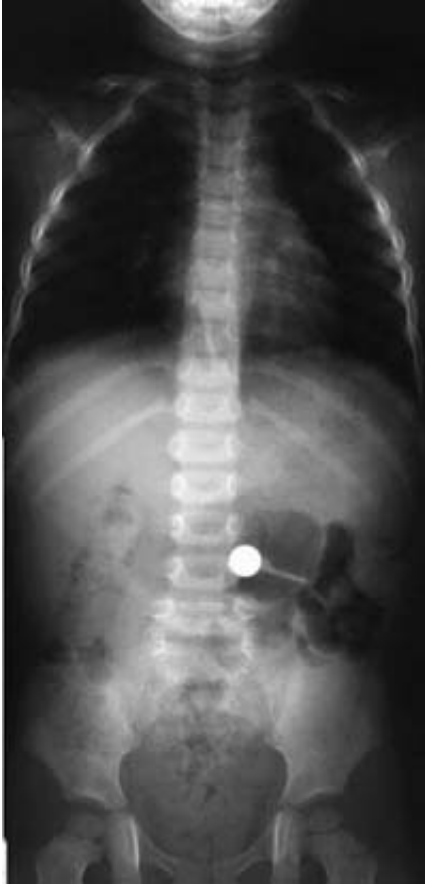Dr. \_\_\_\_\_

School of Medicine: \_\_\_\_\_

The following emergency case arrived at the Kapiolani Medical Pediatric Emergency Care Center in Honolulu, Hawaii:

A 20 month old girl is brought to the emergency room. According to two older children who were playing with her at the time, she swallowed a coin. They do not know what type of coin was swallowed. However, the emergency room doctor is worried. If it really was a small round coin there is not a critical problem because it may pass through the intestines without causing harm. However, if it is a small round battery used for flashlights, computers, or cameras it is filled with poisonous substances. The battery may be opened during digestion and poison the girl. Surgery will be required to remove a battery. You are the hospital radiologist and asked to take an X-ray of her abdomen and infer what the object might be - you need to make the medical diagnosis.

### X-ray of abdomen



The X-ray of her abdomen is shown on the left.


1. Find and label her stomach.
2. Identify and label the metal object.
3. Find and label her heart.
4. Which bones can you identify? Record your data.

The hospital has on file photographs and X-rays of coins and batteries for emergencies.

The first picture below shows X-rays of a series of 5 disc batteries: (face views = B1, B2, B4 and side views B3 and B5) followed by two coins: a dime (face view = D6) and a nickel (side view = N7).

The second picture below is a camera photograph of the same objects.

### X-rays of batteries and coins



Camera photographs of batteries and coins

Using the X-rays and photographs make a chart stating how you would decide whether an object is a battery or coin.

5. A medical reference chart comparing batteries and coins for making a diagnosis:

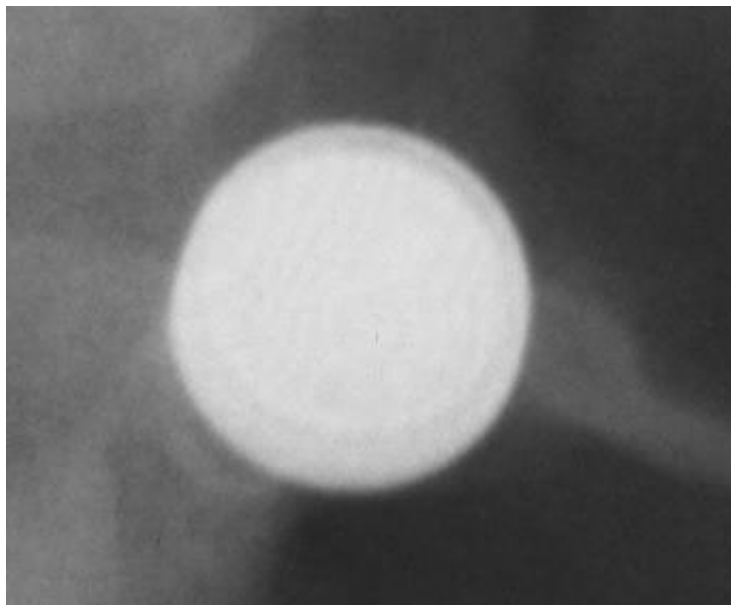
**Battery**

**Coin**

6. Now return to the X-ray of the girl's abdomen. Can you make a diagnosis?

7. You probably would like a close-up or an enlarged view of the object so you can make a better diagnosis. Below is a close up of the object. Make a comparison of the close-up and the file photographs and X-rays of coins and batteries for emergencies

**Close-up X-ray of object**



What is your diagnosis?

What recommendation will you give the emergency room doctor?

Why?

How does your diagnosis compare with your classmates?

**NOTE: THE BABY GIRL WAS TREATED AND FULLY RECOVERED.**  
<http://www2.hawaii.edu/medicine/pediatrics/pemxray/v2c09.html>